



## RESEARCH ARTICLE

### HISTOPATHOLOGICAL CHANGES CAUSED BY *SENGA* SP. IN *CHANNA STRAITUS*

\*Jyoti Shirsat, Vitthal More and Sneha Wankhede

Department of Zoology, Government College of Arts and Science Aurangabad (M.S), India

Received 04<sup>th</sup> July, 2018; Accepted 27<sup>th</sup> August, 2018; Published 30<sup>th</sup> September, 2018

#### ABSTRACT

The present work deals the histopathological study of fresh water fish *Channa striatus* infected with cestode parasite *Senga sp.* The study reveals the mechanical damage cause by the parasite to the intestinal tissue of the fish which which includes shortening and damaging villi, thickening of the muscle layer, destruction of the villi, hold fast penetration of the mucosa and the damage of both the mucous and submucous membranes as compared with the normal intestinal tissue.

**Key words:** Histopathology, *Senga sp.*, *Channa striatus*, Mucosa, Intestinal tissue and Villi.

**Copyright** © 2018, Jyoti Shirsat et al. This is an open access article distributed under the Creative Commons Attribution License, which permits unrestricted use, distribution, and reproduction in any medium, provided the original work is properly cited.

**Citation:** Jyoti Shirsat, Vitthal More and Sneha Wankhede, 2018. "Histopathological changes caused by *Senga sp.* In *Channa striatus*" *International Journal of Current Research in Life Sciences*, 7, (09), 2659-2660.

#### INTRODUCTION

The digestive tract of many fishes has been shown to be a favorite environment for the establishment and growth of pathogenic organisms. Endoparasitic helminths often induce inflammation and modification of the structure and function of local tissues (Castro, 1992). According to Sharkey (1992), the inflammation consists of a complex series of homeostatic mechanisms involving the immune, nervous and circulatory systems in response to tissue injury or infection. Thus the host parasite relationship results in the gain of one organism and the loss of another and leads to various diseases and disorders. Naturally it is important to study this relationship, not because of their parasitological value but for the relative existence of mankind. Helminths infect almost all the regions of the alimentary tract of fish. Any damage to the alimentary canal will alter the physiological activities of fish. For cestode parasites the most favourable and selected site is the alimentary canal, and the reason is to meet their primary need of food from the host. Cestodes have also been found to infect many fish and cause pathological effects on the host. In some cases the parasites have caused severe changes in the host. Others who have reported on the cestode infection in fishes are Ahmed and Muhammad, (1979); Satpute and Agarwal, (1974a and 1974b); Pronina and Pronin, (1982); Chakravarthy and Tandon, (1984); Chakravarthy and Veena, (1989); Chubb, (1982); Hasnain, (1992). Therefore, an attempt has been made to assess the histopathological changes induced by the parasite *Senga sp.* infected in the intestinal tissue in *Channa striatus*

#### MATERIAL AND METHODS

The specimens of freshwater fish *Channa striatus* (Lacepede) were collected from Kaigaon Toka, Dist Aurangabad during year 2014-2015. The animals were packed in ice and brought to the laboratory for examination. During the parasitological examination, the intestines and liver were examined under stereomicroscope to observe the degree of infection. The tapeworms were collected, placed in saline solution, free from the adhering mucus by gentle shaking, flattened, processed and stained for morphological studies. They were identified as *Senga sp.* Pieces of proximal liver (2-3 cm) containing tapeworms were fix in Bouin's solution for 24 hrs. The fixed materials were processed through ascending grades of alcohol, dried in a wax miscible agent and impregnated in wax (M.P 58° to 60°C). Transverse sections were taken with the help of rotary microtome at 6 µm thickness. The sections were floated on warm water at 48°C and mounted on clean slides coated with egg albumin. The mounted, unstained sections were de-waxed in three stages of xylene, 1 minute each, and stained with haematoxylin and eosin (Bullock, 1978). The stained and mounted sections were examined under light microscope. The photomicrographs were taken with the help of camera. These slides were identified by using keys "Systema Helminthum" (Yamaguti, 1956).

#### RESULTS AND DISCUSSION

After cestode parasite *Senga sp.* infection there is a drastic alteration which leads to the destruction of the internal anatomy, resulting in the total change of its appearance of the infected fish *Channa striatus* which includes shortening and damaging villi, (Fig. 2) thickening of the muscle layer,

\*Corresponding author: Jyoti Shirsat, Vitthal More,  
Department of Zoology, Government College of Arts and Science  
Aurangabad (M.S), India.

destruction of the villi, hold fast penetration of the mucosa and the damage of both the mucous and submucous membranes as compared with the normal intestinal tissue (Fig. 1)

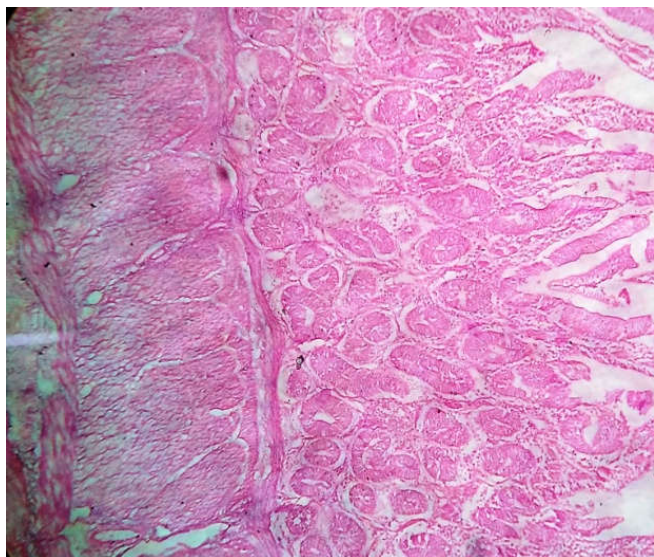


Fig. 1. Normal Intestinal tissue of *C. striatus*

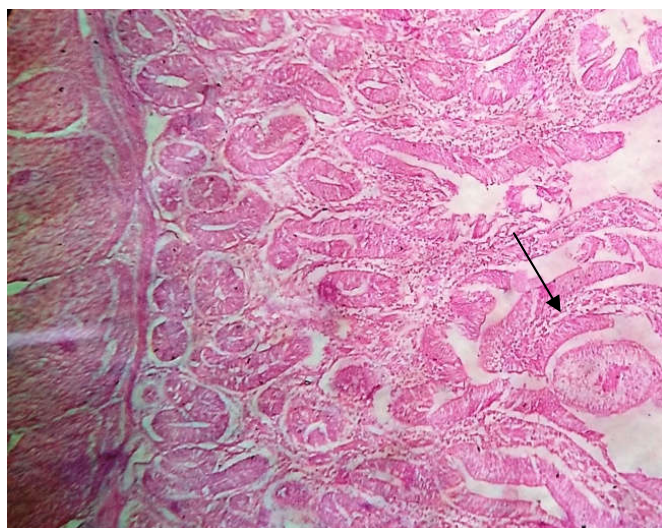


Fig. 2. Infected Intestinal tissue of *C. striatus*

Kanth and Srivastava (1984) observed same kind of histopathological changes in the intestine of *Heteropneustes fossilis* infected with monozoic caryophyllid tape worm, *Lytocestoides fossilis*. Recently Kaldate *et al.*, (2012) observed the intestine where in extensive damage caused to the villi. The villi are erupted at certain region of intestine. The result of this infection causes the intrusion of muscularis layer where the submucous membrane is totally shrunken in *Mastacembelus armatus* infected with *Senga* sp.

**Acknowledgement:** The author is very much thankful to the Principal of Government College of Arts and Science Aurangabad (M. S.) for providing the laboratory facilities during this work.

## REFERENCES

- Castro G.A. 1992. Intestinal physiology in the parasitized host: integration, disintegration, and reconstruction of systems. *Annals of the New York Academy of Sciences*, 664, 369-379.
- Chakravarthy, R and Veena, 1989. Caryophylliasis in the cat fish, *Clarias batrachus* L. some histopathological observations. *Proc. Indian Acad. Sci. Anima Sci.*, 98:127-132
- Chakravarthy, R. and Tandon, V. 1989. Histochemical studies on *Lytocestus indicus* and *Djombanjia penetrans*, Caryophyllidean cestode parasites *Clarias batrachus* (L). *Helminthologia (British)*, 26:259-274.
- Chubb, J.C. 1982. Seasonal occurrence of helminthes in fresh water fishes. Part.IV. Adult Cestoda, Nematoda and Acanthocephala. *Advances in Parasitol*, 20;1-292.
- Hasnain, M., (1992). New cestoda *Senga chauhani* sp.nov. from a fish host *Channa punctatus* from Jamshedpur. *Indian J. Helminthol.* 44(2):121-127.
- Kaldate K.D., Aade U.D and Wankhede H.J. 2012. Histopathological study of ptychobothriid tapeworm in Freshwater fish *mastacembelus armatus* (lecepede, 1800) From Aurangabad district (MS). *Indian Streams Reserach Journal*, Vol.2,Issue.II/March ; 12pp.1-4
- Kanth L.K and Srivastava L.P. 1984. Host-parasite relations in monozoic tape worm, *Lyto-cestoides fossilis* infection of fresh water fish, *Heteropneustes fossilis* (Bloch). *Current science*, 53: 11-22.
- Pronina, S.V. and Pronin, N.M. 1982. Structure of the digestive tract of healthy pike *Esox lucius* (Esoxidae) and of those fishes infected with the cestode, *Trisaenophorus* (Pseudo R phyllidea, *Trisaenophoridae*) *VOPR IKHTIOL.*, 22(4): 641-648.
- Satpute L.R. and Agarwal S.M. 1974a. Seasonal infection of *Clarias batrachus* (L) by *Lytocestus indicus* Moghe, 1931 and parasitic effects on its hematology and histopathology. *Ind. J. Exp. Biol.*, 12:584-586. 29.
- Satpute, L.R and Agarwal, S.M. 1974 b. Diverticulosis of the fish duodenum infected with cestodes. *Ind. J. Exp. Biol.*, 12; 584-586.
- Sharkey K.A. 1992. Substance P and calcitonin gene-related peptide (CGRP) in gastrointestinal inflammation. *Annals of the New York Academy of Sciences*, 664, 425-442.
- Yamaguti, S 1956. *Systema Helminthum* Vol-II. The cestode of vertebrates. Interscience publ. New York and London, 1-860.

\*\*\*\*\*